

## CASE REPORT

# Treatment of AAA and Iliac Aneurysm with Endovascular Stent-graft

Dr. Charles Thompson, M.D. – Orlando Regional Medical Center, Orlando, FL

### CASE REPORT

We report on the successful deployment of the Endologix Powerlink unibody bifurcated stent-graft (Irvine, CA) in a 62 year old male presenting with an abdominal aortic aneurysm and left hypogastric aneurysm. M2S provided 3-D reconstruction of the CT scan.

The patient was scheduled for an open repair of abdominal aortic aneurysm, however at the time of surgery a pancreatic pseudocyst was encountered and drained. He was therefore scheduled for an endovascular repair of his aneurysmal disease.

Pre-op measurements show a proximal infrarenal aortic neck diameter of 21.5 mm with a distal neck diameter of 26.0 mm. The proximal neck length is 21.0 mm. The aortic aneurysm diameter measures 52.0 mm. The renals to aortic bifurcation distance is 122.9 mm and the diameter of the aortic bifurcation is 27.9 mm. The minimum right common iliac diameter is 20.5 mm. The length of the aortic bifurcation to the right hypogastric is 63.7 mm. The left common iliac minimum diameter is 18.5 mm. There is a left common iliac angle of 65.9 degrees. The length from the aortic bifurcation to the left hypogastric is 76.0 mm. The right external iliac diameter is 8.5 mm and the left external iliac diameter is 9.0 mm.

### METHOD

The patient's right side was chosen to deliver the Powerlink bifurcated system with the contralateral side on the left. Cut downs were performed on both sides. A 0.035" stiff guidewire was advanced into the thoracic aorta through the dual lumen catheter per standard procedure. The device limb wire was advanced into the central lumen of the dual lumen catheter. The Powerlink bifurcated system was loaded onto the stiff guidewire and advanced above the aortic bifurcation. The outer sheath was retracted to separate the iliac limbs. The delivery catheter was retracted to position the Powerlink on the aortic bifurcation and the stent-graft was deployed.

Based on the patient's renal to aortic bifurcation length of 122.9 mm, a 28-16-140BL was chosen. The proximal diameter is 28 mm, the iliac limb diameters are 16 mm and the total length is 140 mm. A 28-28-75L proximal cuff was used to add length to reach the renals. The cuff has a proximal diameter of 28 mm, a distal diameter of 28 mm and a total length of 75 mm.

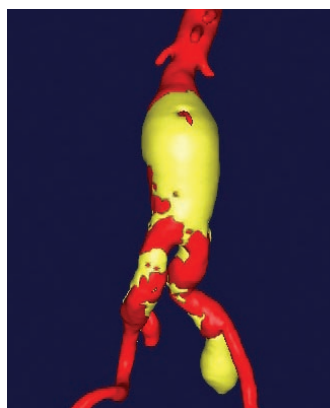


Figure 1. Pre-op

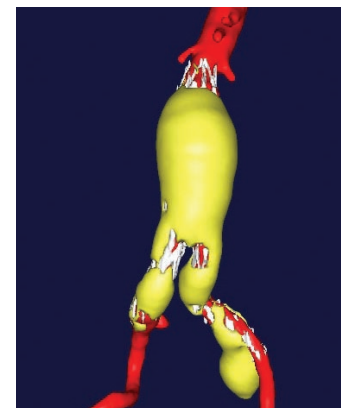


Figure 2. Six Week

A 16-16-88L was implanted on the left side to extend the stent-graft past the coiled left hypogastric artery. The limb extension has a proximal diameter of 16 mm, a distal diameter of 16 mm and a total length of 88 mm. A 20-20-55L limb extension was implanted on the right side. Seal was achieved above the right hypogastric. The limb extension has a proximal diameter of 20 mm, a distal diameter of 20 mm and a total length of 55 mm.

### RESULTS

The Powerlink AAA stent-graft was successfully implanted. Angiography showed the stent-graft in good position without evidence of endoleak. There were no complications. Patient follow up included a six week CT scan with M2S reconstruction. Pre-op and six week M2S images are shown in Figures 1 and 2.

### CONCLUSION

The patient had endovascular repair of abdominal aortic aneurysm and left hypogastric aneurysm. We chose to implant the Powerlink stent-graft because we could anatomically fix the unibody at the bifurcation to provide stability in the iliac aneurysm. The abdominal aortic aneurysm does appear to be shrinking at the time of the six week CT. The Powerlink appears to have a positive effect on aneurysm morphology demonstrated by decreasing AAA diameter and volume over time. The long main body and column strength of the Powerlink may contribute to the findings. The Powerlink clinical trial five year data shows no wire fracture or graft abnormalities. Durability and classical remodeling look to be benefits of the Powerlink AAA stent-graft.