

CASE REPORT

Treatment of Reverse Taper Neck Anatomy with Endovascular AAA Stent-graft

CASE REPORT

A pivotal multicenter trial of the Powerlink device was performed in patients with infrarenal abdominal aortic aneurysm. The trial included both test patients receiving the Powerlink and concurrent surgical controls. A total of 258 patients (192 test and 66 control) were enrolled. FDA approval was received on October 29, 2004. The Powerlink is a unibody bifurcated endograft for repair of AAA. Its stented endoskeleton is self-expanding and is covered with an ePTFE fabric. The Powerlink is surgically implanted through one surgically exposed femoral artery and a contralateral 9 French puncture.

We report on four year follow up of a patient who was enrolled in the pivotal trial. MMS (Medical Metrx Solutions) is the core lab for the clinical trial. MMS offers the service of 3D reconstruction based on spiral CT scans.

The patient has a reverse funnel neck. The proximal aortic neck diameter is 20.1 mm and the distal aortic neck diameter is 26.0 mm. The proximal neck length is 15.0 mm and severe thrombus is present at the proximal neck. The proximal neck angle is 44.9 degrees. The maximum aneurysm diameter is 53.4 mm and the diameter of the aortic bifurcation is 20.7 mm. The length from the lowest renal to the aortic bifurcation is 123.8 mm. The proximal right common iliac diameter is 12.3 mm and the distal right common iliac diameter is 10.8 mm. The length from the aortic bifurcation to right hypogastric is 84.9 mm. The proximal left common iliac diameter is 10.3 mm and the distal left common iliac diameter is 12.7 mm. The length from the aortic bifurcation to the left hypogastric is 72.6 mm. The right external iliac diameter is 6.2 mm and the left external iliac diameter is 5.9 mm. (Figure 1)

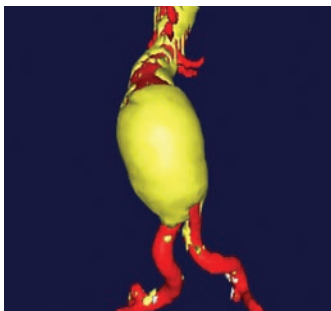


Figure 1. Pre-op

METHOD

A 28-16-155BL stent-graft was chosen based on the patient's pre-op measurements. The stent-graft proximal diameter is 28 mm, the limb diameter is 16 mm and the total stent-graft length is 155

mm. The patient's renal to aortic bifurcation distance is 123.8 mm. The main body of the selected Powerlink is 100 mm. The Powerlink was placed at the lowest renal artery and no proximal cuffs or limb extensions were used.

RESULTS

The Powerlink AAA stent-graft was successfully implanted. Patient follow up includes CT scans and MMS reconstructions through four years. One, two, three and four year MMS images are shown in Figures 2,3,4 and 5. The data is shown in Table 1.

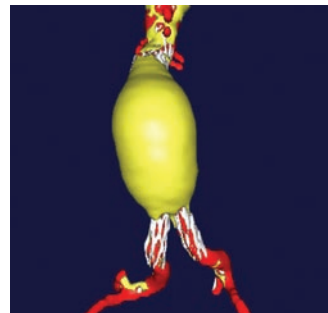


Figure 2. One Year

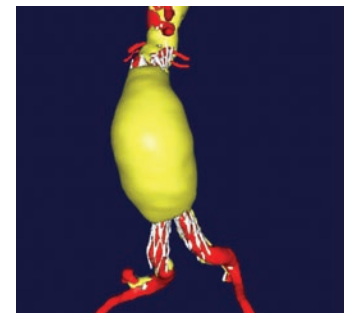


Figure 3. Two Year

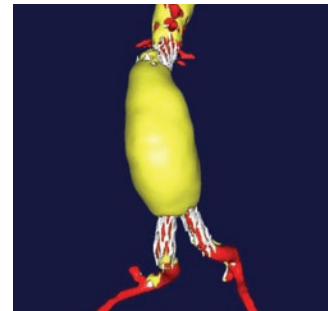


Figure 4. Three Year

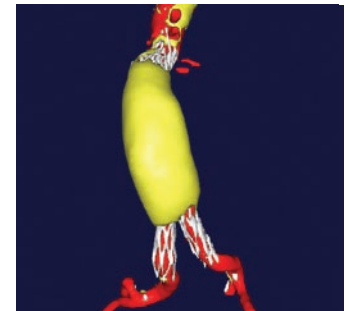


Figure 5. Four Year

CONCLUSION

The patient data obtained through four years shows continuing reduction in maximum AAA diameter and AAA volume. The data is an example of a type of classical remodeling seen in some patients with Powerlink implants. The Powerlink appears to have a positive effect on aneurysm morphology demonstrated by decreased aneurysm diameter and volume over time. The long main body and column strength of Powerlink may contribute to the findings. No migration, graft related endoleak, wire fracture or graft defect have been identified during patient follow up. Durability and classical remodeling look to be benefits of the Powerlink AAA stent-graft.

Table 1

Time Period	Pre-op	One Year	Two Year	Three Year	Four Year
Maximum AAA Diameter	53.4 mm	52.6 mm	51.2 mm	48.5 mm	42.8 mm
Aneurysm Volume	185.5 ml	195.1 ml	170.6 ml	150.1 ml	124.6 ml